CASE REPORT 08 | 2010

camlog

a perfect fit ™

THE EARLY ABUTMENT TECHNIQUE

COMBINATION OF OPTIMUM TISSUE RETENTION WITH MAXIMUM PATIENT COMFORT

Dr S. Marcus Beschnidt
Baden-Baden, Germany

Dr S. Marcus Beschnidt has a private dental practice in Brenner's Park-Hotel & Spa in Baden-Baden. He is a specialist in prosthetics (DGZPW – German society for dental prosthetics and materials science), he is certified in implantology by the DGI (German society for implantology) and is acknowledged as a specialist in implantology by the BDIZ (Federal association of implantology dentists in Germany). Dr Beschnidt is an active member of the European Academy of Esthetic Dentistry (EAED). He has published numerous scientific papers in national and international journals, and he lectures in Germany and in other countries. Dr Beschnidt has been using the CAMLOG® Implant System for 11 years and can therefore take advantage of many years of experience.

IMPLANTS USED

Tooth	18	17	16	15	14	13	12	11	21	22	23	24	25	26	27	28
Impl. type								SL								
Impl. length								16.0								
Impl. Ø								5.0								
Impl. surface								P								

Tooth	48	47	46	45	44	43	42	41	31	32	33	34	35	36	37	38
Impl. type																
Impl. length																
Impl. Ø																
Impl. surface																

Impl. type ROOT-LINE (RL) / SCREW-LINE (SL) **Impl. surface:** Promote (P) / Promote Plus (PP)

PROSTHETICS

- ☐ standard
- ☒ platform switching
- ☐ removable
- ☐ fixed
- ☒ crown
- ☐ bridge
- ☒ cement-retained
- ☐ screw-retained
- ☐ partially edentulous
- ☐ edentulous
- ☐ others

- ☐ Universal abutment
- ☐ Esthomic® abutment
- ☐ Telescope abutment
- ☐ Gold-plastic abutment
- ☐ Ceramic abutment
- ☒ Individual zirconium abutment on titanium base
- ☐ Logfit® abutment
- ☐ Locator® abutment
- ☐ Ball abutment
- ☐ Bar abutment
- ☐ others

INFORMATION ON PATIENT AND TREATMENT

The female patient was 40 years old at the start of treatment. The high smile line and the thin gingival phenotype significantly complicated the case. Tooth 11 and tooth 12 had grayish crowns and livid gums. The roots of both teeth had been treated, before a metal pin had been inserted in tooth 11 alio loco. An apicectomy had also been conducted on tooth 12, which had left scarring with partial retraction of the gingiva. The apicectomy was not fully healed when the medical history was taken, and the root canal filling at tooth 12 appeared too short apically.

Tooth 11 had to be atraumatically removed, and we decided in favor of an immediate implant placement followed by a temporary restoration using a temporary shell crown. An impression was taken during the procedure with the "early abutment technique" to allow the implant position to be transferred to the master cast for early manufacture of the final abutment. After regenerative measures for rebuilding hard and soft tissue by the pouch technique and delivery of the long-term temporary denture, the patient was discharged. The final abutments were placed only two days later and were not unscrewed, again. This was the only way of establishing a thick peri-implant soft-tissue collar and minimizing the soft-tissue retraction. The final full-ceramic crown was placed 12 months later.

Initial situation

Fig. 1: The patient has a smile line level with and above the cervix. The line of the gingiva and upper lip appears irregular. Incipient papilla loss can be seen in regions 11 to 13.

Fig. 2: The gum shows scarring as a result of a previous apicectomy. The crowns appear gray. The gingiva has a livid discoloration, where the dark root stumps show through because of the thin phenotype.

Fig. 3: The crowding of teeth 11 and 12 and the convoluted dentition made the situation implantologically and esthetically very difficult.

Atraumatic removal of the residual root

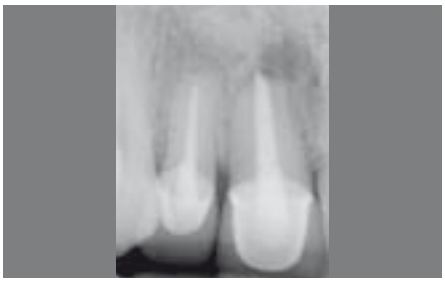

Fig. 4: A metal pin placed alio loco is visible at tooth 11. The apicectomy is not healed. The root canal filling at tooth 12 appears too short at the apex.

Fig. 5: To remove tooth 11, a computer-controlled injector (The Wand, Milestone) was used for a palatal injection. This protects the scarred tissue almost completely and does not affect the blood supply.

Fig. 6: Atraumatic removal of the residual root 11. The inflamed tissue was completely scraped out.

Implant placement

Fig. 7: The metal pin is clearly visible on the apex of the removed root.

Fig. 8: Accurate measurement of the alveolar cavity is essential with immediate implant placement. This is the only way to find out where bone is and whether it is intact. The implant diameter is measured with a vernier caliper (Zepf Medizintechnik).

Fig. 9: The alveolar cavity is also probed with the periodontal probe to detect any defects on the alveolar margin. The gingival height is analyzed as well to allow an estimate of future resorption.

Impression and temporary abutment

Fig. 10: The planned implant axis and the distances to neighboring structures can be checked with the form drill inserted into the alveolar cavity.

Fig. 11: Insertion of a CAMLOG® SCREW-LINE Promote® implant 5 mm diameter and 16 mm long.

Fig. 12: Impression-taking with an impression post, open tray, for fabrication of the "early abutment" and long-term temporary crown.

Fig. 13: Details of the impression for precise transfer of the implant position to the master cast.

Fig. 14: Relining of a temporary shell crown on an intraorally marked and laboratory-customized titanium abutment. In low heights, titanium with its greater stability is more suitable than PEEK.

Fig. 15: The temporary shell crown is positioned with the aid of an insertion key.

Bone and soft-tissue regeneration

Fig. 16: The labial gap between implant and alveolar cavity should be filled with a non-resorbable bone replacement material for bone and soft-tissue regeneration.

Fig. 17: The soft tissue is compressed with a free subepithelial connective tissue graft. A pouch is prepared without vertical incision and without injuring the papillae.

Fig. 18: Connective tissue graft **in situ**; it is important to keep the papillae intact.

Early abutment and long-term temporary denture

Fig. 19: In the meantime, the provisional crown is trimmed in the laboratory; it can be cemented in after screwing in the titanium abutment.

Fig. 20: A ceramic abutment cemented to a titanium base was fabricated within two days. The zirconium-oxide-ceramic has a smaller diameter for platform switching.

Fig. 21: The definitive screw-retained abutment on the lab analog.

Fig. 22: The long-term temporary crown in region 11 was splinted with the crown on the natural stump.

Fig. 23: Two days **post-op**: The temporary titanium abutment is replaced with the definitive ceramic abutment.

Fig. 24: The long-term temporary crown is fixed; it will remain **in situ** for at least six months, in this case, even for 12 months.

Additional measures

Fig. 25: A Michigan splint protects the surgical site from pressure. It should be worn for eating and sleeping for at least four weeks.

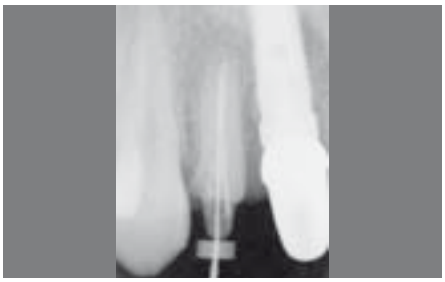

Fig. 26: The root-canal treatment in region 12 is revised.

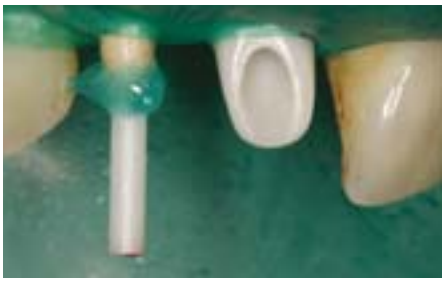

Fig. 27: After revision of the root-canal treatment and internal bleaching, a ceramic pin was fitted into the root canal and cemented in.

Impression-taking for definitive restoration

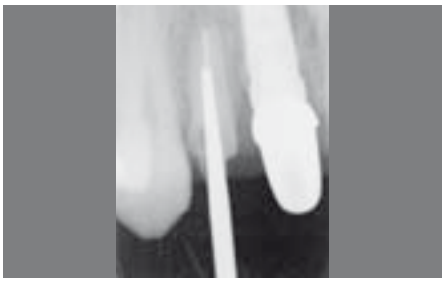

Fig. 28: X-ray examination of the inserted ceramic pin.

Fig. 29: Impression-taking of the definitive abutment and the natural post for manufacture of the definitive full-ceramic restoration.

Fig. 30: The position of the abutment is transferred to the master case with the aid of a plastic coping.

Situation 12 months after implant placement

Fig. 31: 12 months **post-op**, the tissue has matured and the gingival recession is minimal.

Fig. 32: 12 months **post-op**, the definitive full-ceramic crowns are placed; the dentition was compensated to the contralateral teeth. Care was taken not to crush the papillae between 11 and 21.

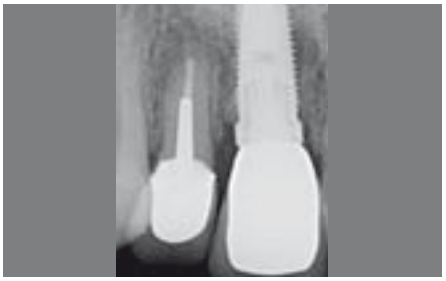

Fig. 33: X-ray check one year after loading.

CONCLUSIONS

In esthetically high-risk cases (high smile line, thin gingiva, prior operations), it is important to carry out all required measures in only **one** surgical procedure if at all possible: atraumatic tooth extraction, scar correction, gingiva thickening, implant placement and possibly bone grafting. In this case, a partial socket preservation was conducted. Using the "early abutment technique" after two days – during the healing phase – the definitive ceramic abutment was placed and left **in situ**. As a result, the wound adhered to the abutment, and there was a tissue adhesion in the implant shoulder region. This procedure has been in use in our practice since 2002 and has proven successful. A decisive factor is the application of minimally invasive microsurgery: few vertical incisions, minimal incisions, checking the bone and soft-tissue situation by probing. The healing phase should last at least six to nine months to allow the tissue to mature. In our experience, platform switching is also required after formation of the soft tissue, because the soft tissue has more space with this technique. The combination of techniques described here offers a way of increasing the probability of optimum tissue retention with the right indications.

Before

Fig. 34: Initial situation with the two root-treated teeth in regions 11 and 12. An apicectomy was also conducted at tooth 12. The high smile line and the thin gingival phenotype significantly complicated the case.

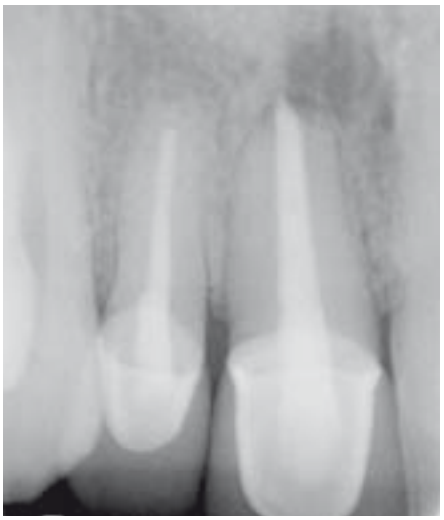

Fig. 35: A metal pin placed alio loco is visible at tooth 11. The apicectomy is not yet completely healed. The root canal filling at tooth 12 appears too short at the apex.

After (2 years after loading, 1 year after prosthetic restoration)

Fig. 36: Situation two years after immediate implant placement and one year after the definitive prosthetic restoration.

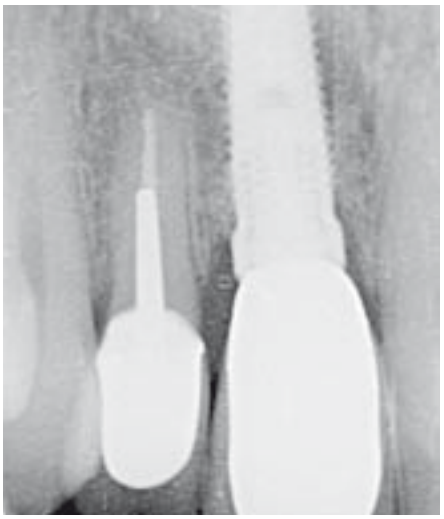

Fig. 37: X-ray check five years after loading.

NOTES

REFERENCES

ABRAHAMSSON I, BERGLUNDH T, SEKINO S, LINDHE J
Tissue reactions to abutment shift: an experimental study in dogs. Clin Implant Dent Relat Res. **2003**; 5(2): 82-88.

SMALL PN, TARNOW DP
Gingival recession around implants: a 1-year longitudinal prospective study. Int J Oral Maxillofac Implants. **2000** Jul-Aug; 15(4): 527-532.

KAN JY, RUNGCHARASSAENG K, UMEZU K, KOIS JC
Dimensions of peri-implant mucosa: an evaluation of maxillary anterior single implants in humans. J Periodontol **2003** Apr; 74(4): 557-562.

GRUNDER U
Stability of the mucosal topography around single-tooth implants and adjacent teeth: 1-year results. Int J Periodontics Restorative Dent. **2000** Feb; 20(1): 11-17.

SCHROPP L, ISIDOR F, KOSTOPOULOS L, WENZEL A
Interproximal papilla levels following early versus delayed placement of single-tooth implants: a controlled clinical trial. Int J Oral Maxillofac Implants. **2005** Sep-Oct, 20(5). 753-761.

CARDAROPOLI G, LEKHOLM U, WENNSTRÖM JL
Tissue alterations at implant-supported single-tooth replacements: a 1-year prospective clinical study. Clin Oral Implants Res. **2006** Apr; 17(2): 165-171.

ABRAHAMSSON I, BERGLUNDH T, GLANTZ PO, LINDHE J
The mucosal attachment at different abutments. An experimental study in dogs. J Clin Periodontol. **1998** Sep; 25(9): 721-727.

WELANDER M, ABRAHAMSSON I, BERGLUNDH T
The mucosal barrier at implant abutments of different materials. Clin Oral Implants Res. **2008** Jul; 19(7): 635-641.

LINKEVICIUS T, APSE P
Influence of abutment material on stability of peri-implant tissues: a systematic review. Int J Oral Maxillofac Implants. **2008** May-Jun; 23(3): 449-456.

CONTACT

Dr S. Marcus Beschnidt
Privatpraxis für Zahnheilkunde
Lichtentaler Allee 1
D-76530 Baden-Baden
Tel: +49 (0)7221 3939719
E-Mail: info@beschnidt.com
www.beschnidt.com

HEADQUARTERS
CAMLOG Biotechnologies AG | Margarethenstrasse 38 | CH-4053 Basel | Switzerland
Phone +41 61 565 41 00 | Fax +41 61 565 41 01 | info@camlog.com | www.camlog.com

camlog